

Computed Tomography Scan Brain With Stroke Cases Haemorage at Dr Haji Adam Malik

Hotben Lubis¹, Liberti Tarigan², Rani Emannuelia Surbakti³

^{1,2}ATRO lecturer Amal Bhakti Yayasan Sinar Medan, Jl. Haji Muhammad Joni No.50, Medan, North Sumatra 20 216

³College student Amal Bhakti ATRO Yayasan Sinar Medan, Jl. Haji Muhammad Joni No.50, Medan, North Sumatra 20 216

Abstract- With the title "Computed Tomography (CT- Scan) Brain Stroke with case Haemorage General Hospital Haji Adam Malik Interest CT scan Brain Stroke with Case Haemorage to show anatomical features and disorders - disorders in which areas of the brain hemorrhage caused terjadinya trauma , The brain is an important organ and can be regarded as the central computer of all organs, central nervous section located within the cranial cavity encased by a powerful brain membrane. Inspection techniques are in use projection AP (supine) on axial cuts at the start of the orbito meatal line until the vertex region aims to show how much fluid in the brain. Where the planes were used in this research that CT- Scan generation III produces four slice each round. As for the best equipment used ready-made CT-Scan (standbay), apron and oxygen. Type of film used thermal blue film specifically designed for the film imager station and packed 125 pieces in one package. In Brain anatomy illustration of a supine patient position seemed abnormalities haemorage stroke on the left frontal and basal ganglia. Image density and high image contrast so that the results ekspertise / reading from a doctor stating the patient suffered a stroke haemorage in the left frontal and basal ganglia (vol +/- 70 cc). In Brain anatomy illustration of a supine patient position seemed abnormalities haemorage stroke on the left frontal and basal ganglia. Image density and high image contrast so that the results ekspertise / reading from a doctor stating the patient suffered a stroke haemorage in the left frontal and basal ganglia (vol +/- 70 cc). In Brain anatomy illustration of a supine patient position seemed abnormalities haemorage stroke on the left frontal and basal ganglia. Image density and high image contrast so that the results ekspertise / reading from a doctor stating the patient suffered a stroke haemorage in the left frontal and basal ganglia (vol +/- 70 cc).

Key Word: Brain and Stroke Haemorrhage

1. Introduction

According Syaifuddin, (1997) The brain is an organ that is important and can be regarded as the central computer of all organs, parts of central nervous located inside the cavity of the skull (cranium) wrapped by the lining of the brain stronger is the pia mater or inner layer, arachnoid or middle membrane, the dura or outer layer. According Sutrisno (2007) Stroke is a neurological disorder that is settled, which is caused by damage to the blood in the brain, which occurred about 24 hours or more. According to Dorland, (1998) Haemorage is an existing understanding to explain the discharge of blood from the veins or bleeding according to Sutrisno, (2007) Stroke there are two types, namely:

- a) Ischemic stroke: a type of stroke that is not accompanied by a brain haemorrhage and a brain tissue death due to blood supply does not cover.
- b) Stroke haemorage: a type of stroke caused by a rupture of blood vessels in the brain or brain blood vessels leak.

Conventional radiography as the most common diagnostic tools can not show abnormalities - abnormalities found in the brain. Therefore examination of computed tomography is a very excellent method to generate each layer of the brain so that abnormalities can be accurately show especially in the cases of stroke haemorage. According to Ballinger, (1986), Computed Tomography (CT) is a picture that is constructed by a computer using an X-ray that is collected from various points around and form part of the so-called scanned so as to produce a picture of a cross-sectional tomographic plane (slice) is sliced from the body ,

2. Research Methods

2.1 Types of research

This study uses descriptive qualitative research. Qualitative descriptive study is a method in researching the status of human groups, an object with the aim of making descriptive, picture or painting in a systematic, factual and accurate about the facts or the truth can be justified.

2.2 Time And Place Research

a) Research time

The research was conducted on January 2016.

b) Research Sites

Place of research conducted at the General Hospital Center H.Adam Malik.

2.3 Data collection technique

At this research stage so that the data obtained data is valid and can be justified, it can be obtained through:

1. Interview

As for the data collection, the researchers conducted interviews with patients, their families, radiographer, radiology specialist doctors and orthopedic specialists (orthopedic surgery).

It thus carried out with the aim to obtain broad and comprehensive data in accordance with current conditions.

2. Observation

Direct observations made by researchers can be realized by recording the form of information related to the radiology room General Hospital H.Adam Malik. Also observe and follow the direct examination Brain CT scan, in order to obtain evidence relating to the object of research.

2.4 Data analysis

Phase analyzing the data is the most important stage in the determination of a study. The data were then analyzed with tujuanmengolah data into information, so that the characteristics or properties of the data can be easily understood and useful to address issues related to the research.

This analysis is based on field observations or experience based on data obtained from interviews and observations followed and the conclusions drawn.

3. Results and Discussion

3.1 result

a. Patient identity

Name : Ny. H
Age : 56 Years
Address : Jln. Unitary Lk V Galang
Gender : Women
Examination : CT-Scan Head
doctors Sender : PPDS Medicine, Dr.
doctors reader : Rudolf H, Pakpahan, Dr, Sp.Rad

b. Examination procedure

a) Reading Request CT scan

Patients present with a letter of referral from a doctor sender to do the scanning of the patient. Patients register keloket CT scan first, then the counter clerk CT-Scan deliver mail request CT - Scan to technologist. Then technologist call the patient's family to ask the patient's history, after which it is being scanned.

b) Administration

Where officers radiographer to enter patient data into the computerized, so that the action taken can be stored in the computer. Where data is entered in the form, the patient's name, no MR her, sex and what action was taken to facilitate officer to criticize medical record medical history / action had been performed on these patients.

c. Patient preparation

Basically there is no special preparation of the patient, but the radiographer can perform a CT-scan technique Brain. Preferably objects that lead to artifacts such as earrings, glasses, hearing aids, hairpins, etc. should be removed.

It's good a radiographer inform and explain carefully about any actions to be taken during the inspection takes place to the family of the patient so that the patient can undergo the examination with lancar.berikan explanation to patients in order to help the patient from moving during the inspection took place.

d. Preparation Tools and Materials

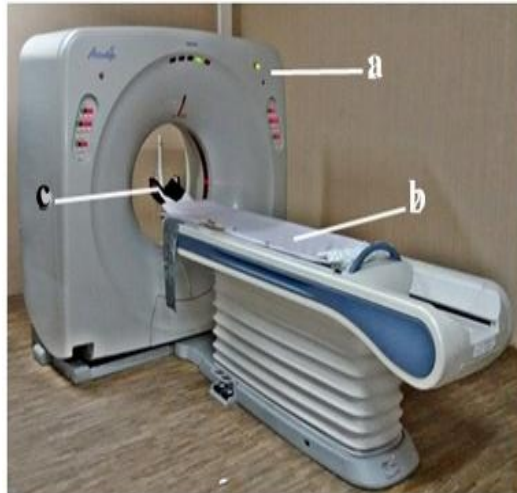

Figure 2. TOSHIBA CT-Scan plane CXXG-005 A
(Dr H. Adam Malik)

Caption :

- 1) gantry
- 2) Examination table
- 3) Head Holder
- 4) Switch forward, backward, up, down

Flight Specifications CT-Scan

Type : Asteion TSX-021B
 brands : TOSHIBA
 Model : CXXG-010A
 Frequency : 50/60 Hz
 Input Power Max : 55 kVA
 output : 120 kV / 300 mA
 135 kV / 260 mA
 No. series Tube : 2AA06X3002
 filter default : Al

e. Mechanical Inspection

- 1) Officers entered the room by entering the patient's identity
 Include: age, sex, registration number by clicking on the menu PATIENT ID.
- 2) The position of the patient
 - a) The patient is positioned supine sleep on an exam table (supine position) by placing the head in a head holder, wherein interpupillary line parallel to the horizontal line of light collimator and neck a little extension.
 - b) Place both upper extremities are next to the patient's body.
- 3) Making the picture
 - a) Adjust the patient to MSP (Mid Sagittal Plane) body parallel / parallel to the longitudinal positioning lights by pressing the 'in' on the gantry.
 - b) Position the head, where Interpupillary line parallel to the horizontal line of light collimator, and little neck extension.

- c) Enter your information / data of patients included: No. ID, Patient Name, Age, Sex, Comment (when using contrast media in the available space on the monitor screen by pressing the ID button on the keyboard), and then press OK.
- d) Select the type of examination or exam protocol routine group by pressing Brain + bone 5mm + 10mm on the keyboard.
- e) Click OK, and then press scanredo on the keyboard until the lamp X-Ray button press to scan in progress.
- f) On the screen appears the image scanogram then set penyudutan axial slices to get a piece of that is: select rotate all, set the slice penyudutan to align with MAI and corners of the eyes and the upper limit and the lower.
- g) Select the move to set up the biggest part Click OK, until gantry formed in accordance with penyudutan wedge angle that is set, and then press the X-Ray and Abort on the keyboard to stop the scan, and then click the vary area to set the scan area (FOV). Then press Ok and X-Ray button to complete.
- h) If the inspection is complete then specify the number of slice images to be printed by selecting the appropriate slice picture with the patient's clinical and starting from the upper limit to the lower limit to the printing to complete.

f. Results Ekpertisi

After examination and processing of the film, the writer describes the evaluation results CT-Scan examination with suspicion of stroke haemorage. Ekpertisi author gives results as follows:
inspection reports

Intratentorial normal cerebellum and IV ventrikel

Supratentorial lesions appear hyperdens left frontal and basal ganglia

Looks midline shift to the right

Looks hyperdens fluid within the ventricular system. Cortical obliterated sulcus in the left hemisphere.

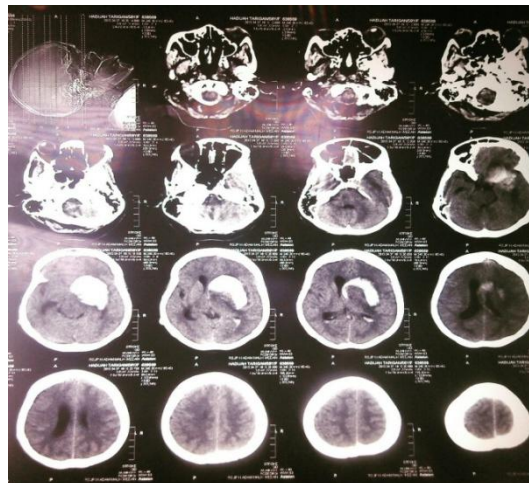


Fig 3.Film computed tomography brain

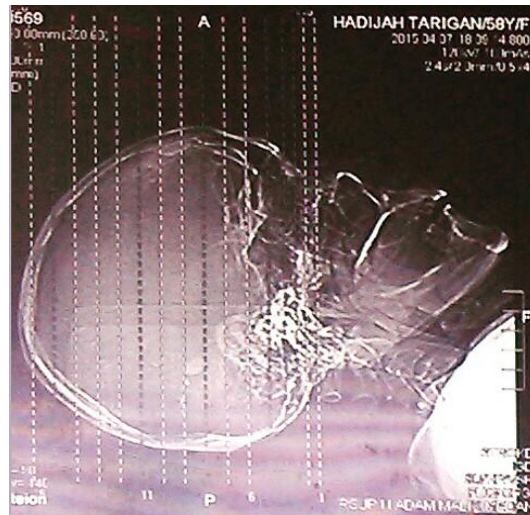

Fig 4. Hadijah brain tomogram Tarin (Dr H. Adam Malik)

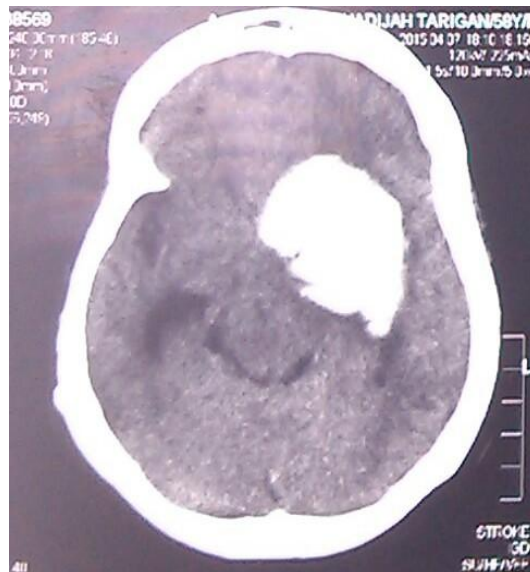

Fig 8. Hadijah brain slice 8 Tarin (Dr H. Adam Malik)

Caption :

- a) left frontal
- b) Left occipital
- c) temporal Left
- d) Right lateral ventricle
- e) Haemorage Left Frontal Lobe

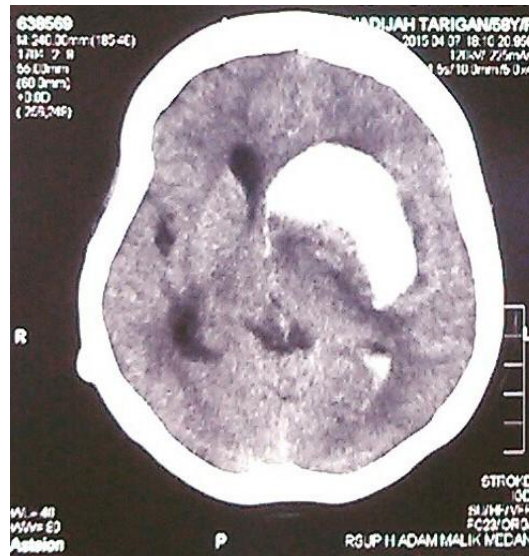


Fig 9. Slice 9 Hadijah Tarin
(Dr H. Adam Malik)

Caption :

- a) frontal Kir
- b) Left occipital
- c) Basal Ganglia Haemorage Left
- d) Basal Ganglia Right
- e) Left parietal

3.2 Discussion

From the results of the CT scan performed on Ny.H Brain General Hospital Center H.Adam Malik found haemorage stroke.

Haemorage Stroke is a type of stroke caused by a rupture of blood vessels in the brain or brain blood vessels leak.

To obtain an optimal density on CT-Scan Brain by plane CT-Scan generation III produces four slice each one scan. Wherein the image generated in the examination with suspicion of stroke haemorage brain, it can be shown clearly and can be interpreted. And if possible radiographer can choose the best type of CT scan that can produce a larger body parts such as the 16 slice, 32 slice, 64 slice and the other so that the scan time used is shortened so that the radiation dose to the patient can be reduced.

In the CT-Scan operator put immobilizing tool that can reduce the patient's movements, namely the head and the head holder straps striping on the body.

By maintaining a dose below the threshold, guarantee the implementation of all actions necessary to limit the possibility of stochastic effects on society.

4. Conclusion

In accordance with the proposal title "Brain CT scan on suspicion of stroke Haemorage", the authors draw some conclusions as follows:

- a) Brain CT scan examination on suspicion of stroke haemorage done using axial CT scan pieces with thick slices of 5 mm orbito meatal starting from the line up to the vertex region.
- b) Examination of brain CT scan on suspicion of stroke haemorage done using a supine position on the examination table.
- c) Examination of brain CT scan requires clear information from the operator to the patient's family and take measures to reduce the movement of the patients examined, namely by putting straiping straps on the body and head holder on the head.
- d) CT-Scan plane that is used for a CT-Scan Brain on suspicion of stroke haemorage that is best which produces four slices each scan.

5. Reference

- [1] Akhadi, (1997), Basics of Radiation Protection. Jakarta: Rineka Reserved
- [2] Ballinger, (1999), Merrill 's Atlas of Radiographic Position and radiologic procedures, St. Louis: Mosby
- [3] BONTRAGER, (2001). Textbook of Radiographic Positioning and Related Anatomy, Fifth Edition. St. Louis: CV. Mosbly Company
- [4] Bushong, (2001), Radiology Science for Technologists, St. Louis: Mosby
- [5] Dorland (1998), A Pocket Dictionary of Medicine, Jakarta: EGD
- [6] Hima, ((1973), Pathology, Jakarta: PT Repro International
- [7] Meredith, (1972), Fundamental Physics of Radiology, Washington: Manchester
- [8] Pearce, (1973). Anatomy And Physiology For Paramedics, Jakarta: Gramedia Pustaka General.
- [9] Sloane, (2004), Anatomy and Physiology For Beginners, Jakarta: EGC
- [10] Syaifuddin (1997), Anatomy and Physiology for Nursing Students, 2nd Edition, Jakarta Book Medical EGC
- [11] Sutrisno, (2007), Srtoke? You Must Know Before You Get It! Jakarta, PT Gramedia Pustaka Utama